Effects of remote, retroactive intercessory prayer on outcomes in patients with bloodstream infection: a randomised controlled trial

Leonard Leibovici

BMJ 2001;323;1450-1451

The painful red eye

Dr. S. Gichuhi

RSVP

- **R**edness
- **S**ensitivity to light
- **V**isual loss
- **P**ain

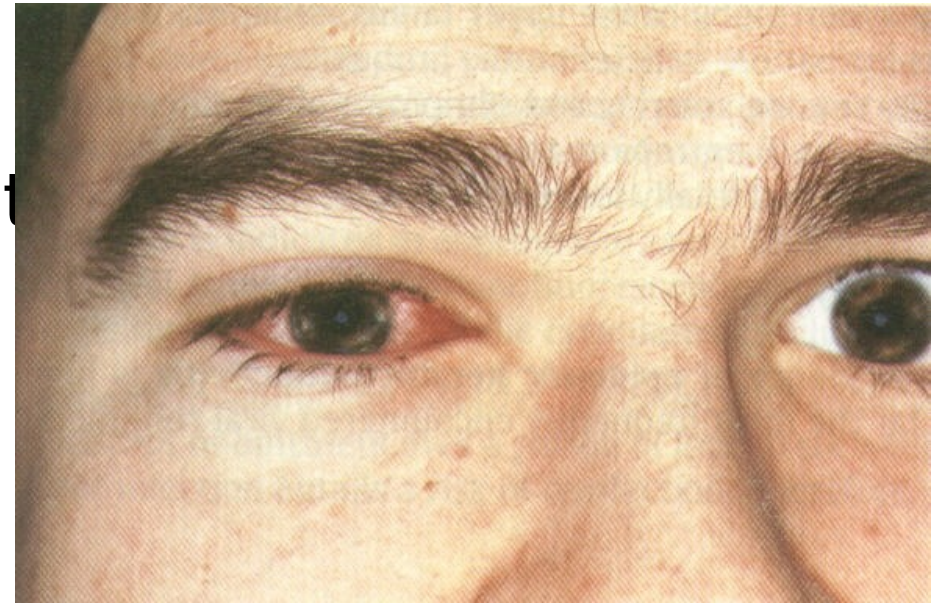

NBC.com

Forms of conjunctival injection.

Conjunctival

Conjunctival disorders; conjunctivitis

Mixed

Corneal disorders with intraocular irritation; corneal ulcerations

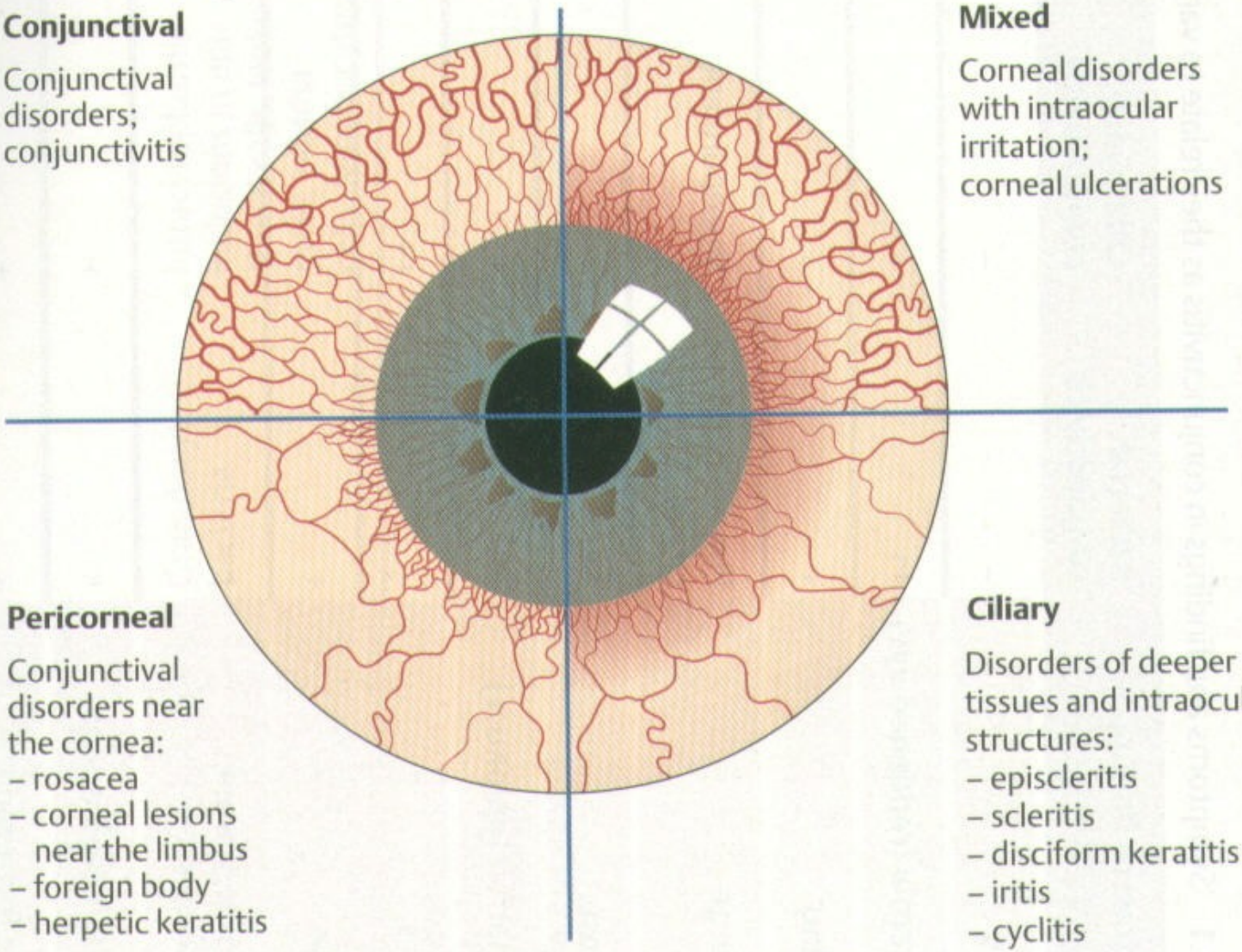

Pericorneal

Conjunctival disorders near the cornea:
- rosacea
- corneal lesions near the limbus
- foreign body
- herpetic keratitis

Ciliary

Disorders of deeper tissues and intraocular structures:
- episcleritis
- scleritis
- disciform keratitis
- iritis
- cyclitis

Fig. 4.6

Causes of moderate-severe pain

1. Cornea
   - ulcer
   - foreign body
   - abrasion
   - erosion
2. Anterior uveitis
3. Scleritis/ Episcleritis
4. Acute angle-closure glaucoma

Mild-moderate pain

1. Conjunctivitis
2. Inflammed pterygium/ pingueculum
3. Blepharitis
4. Stye
5. Superficial punctate keratitis (SPK)
6. Herpes simplex
7. Herpes zoster ophthalmicus

Predisposing factors for corneal ulcers

- Contiguous infection (blepharitis, dacryocystitis)
- Changes in corneal epithelium (dry eyes, Vitamin A deficiency)
- Contact lenses
- Lagophthalmos
- Neuroparalytic disorders
- Trauma
- Topical and systemic immunosuppresive agents

Corneal ulcers

- Herpes simplex
- Fungal keratitis
- Bacterial keratitis
- Mixed infection (uncommon)
- Mooren’s ulcer
- phlyctenulosis

Corneal ulcers

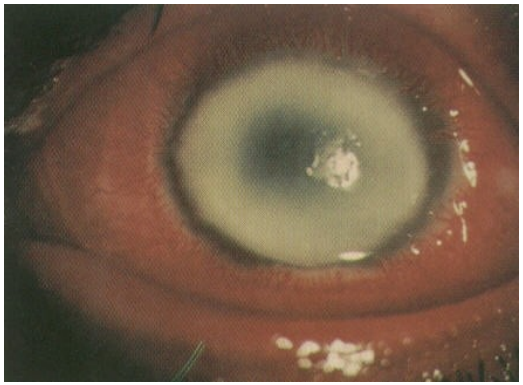

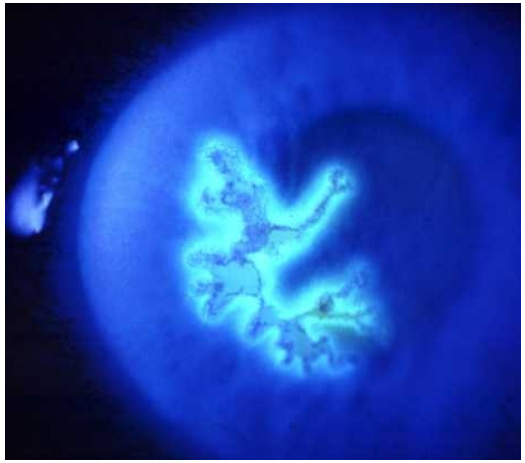

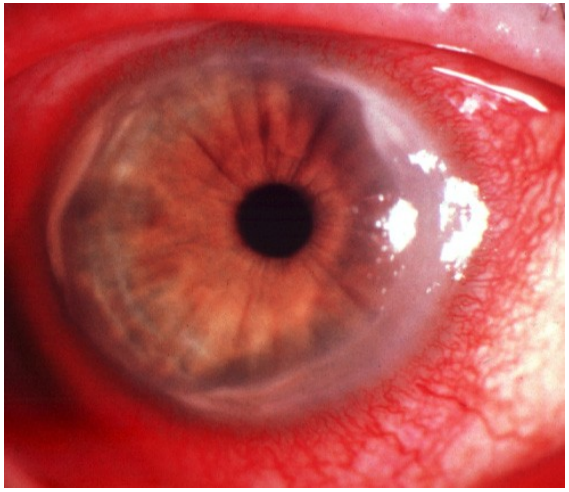

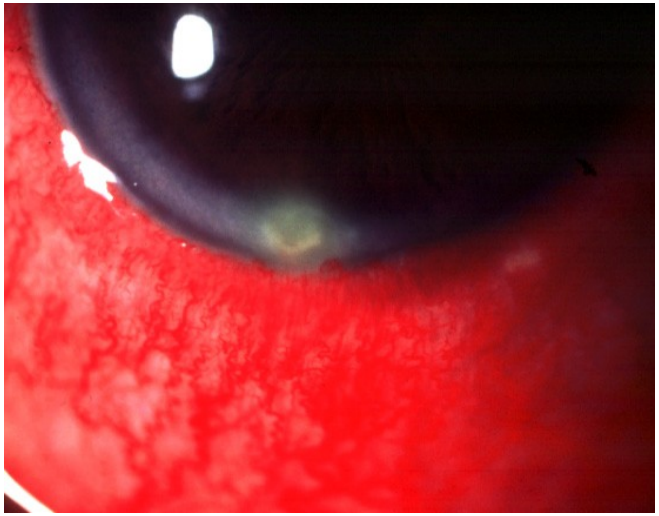

Corneal foreign body

- Welders
- Lathe machines
- Pencils
- Farmers threshing grain

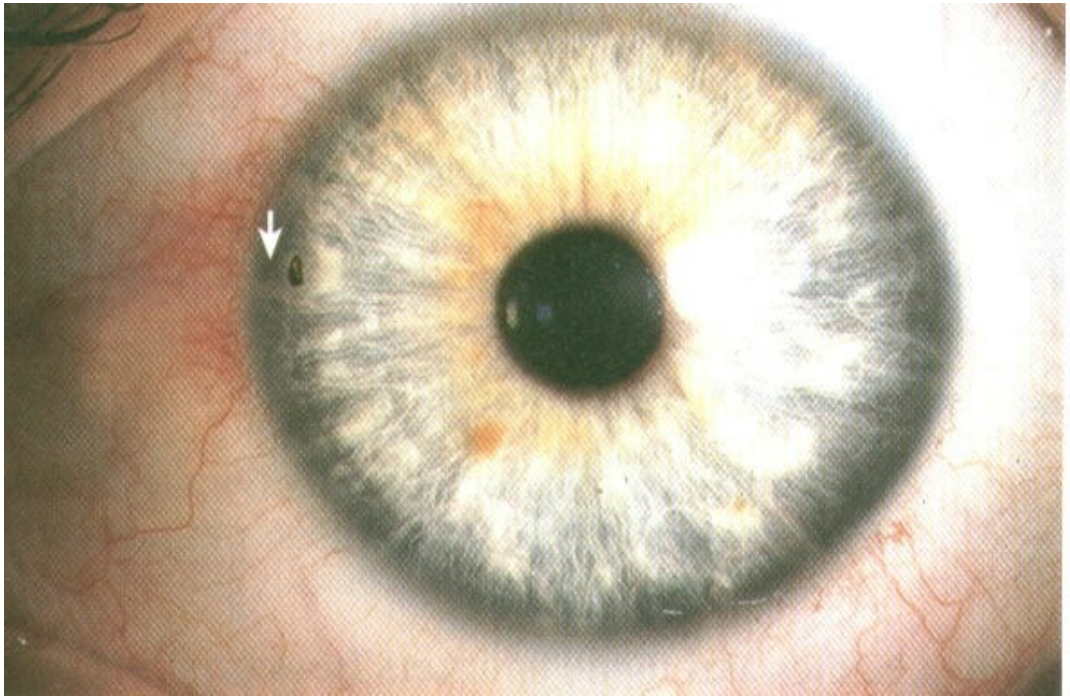

Conjunctival foreign body

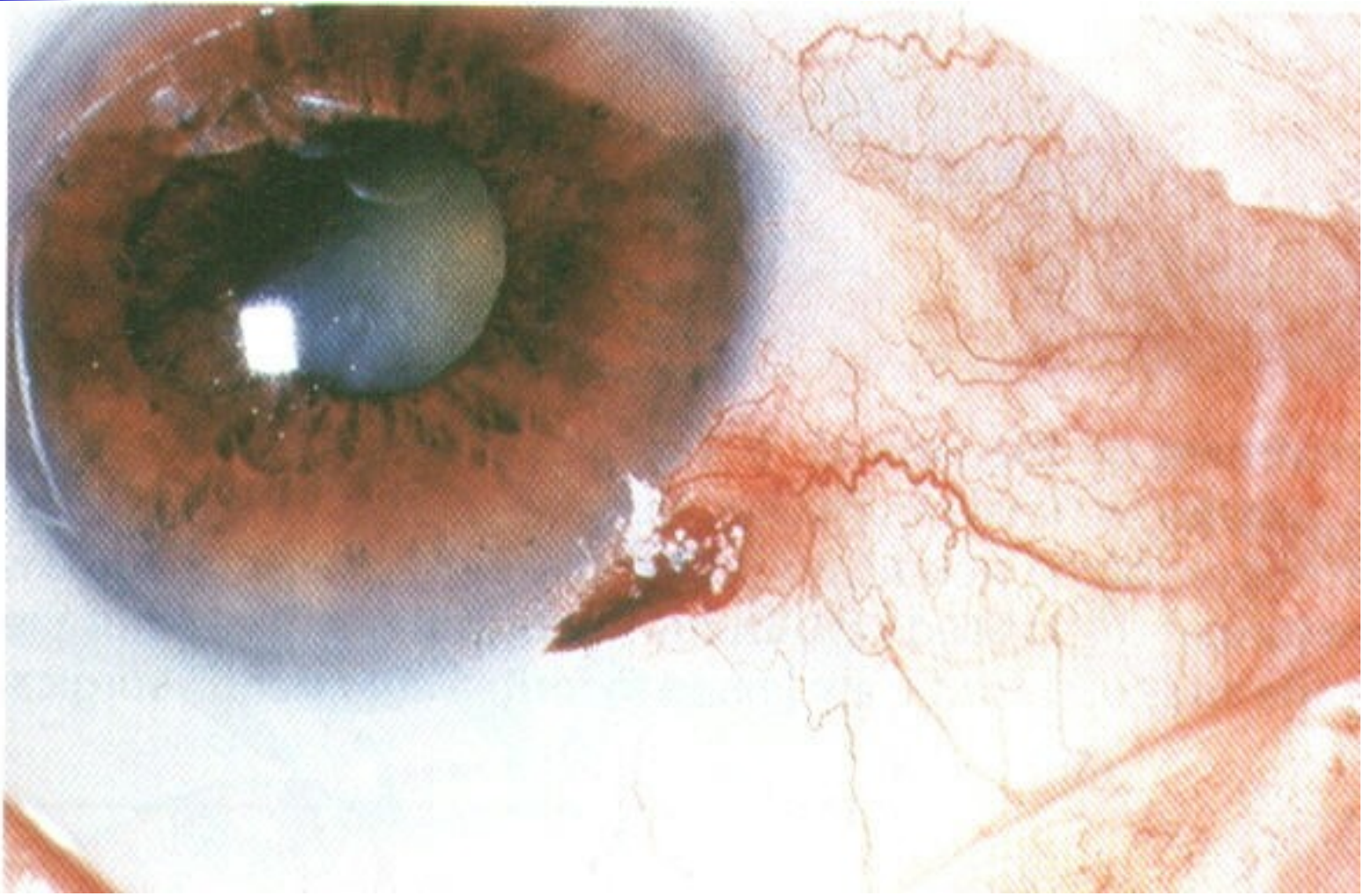

Corneal abrasion/erosion

- Due to retained foreign bodies
- Due to weak epithelium eg epithelial corneal dystrophies
- Rx: Pad with TEO overnight

Anterior uveitis

- Aetiology - mostly unknown
- Symptoms – RSVP,tearing, headache
- Signs – ciliary injection, miosis, cells and protein in the AC, raised IOP
- Differential diagnosis – acute glaucoma
- Treatment – steroids, cycloplegia,
- Prognosis – usually improves in a few days

Complications of uveitis

Posterior synechiae - 30%

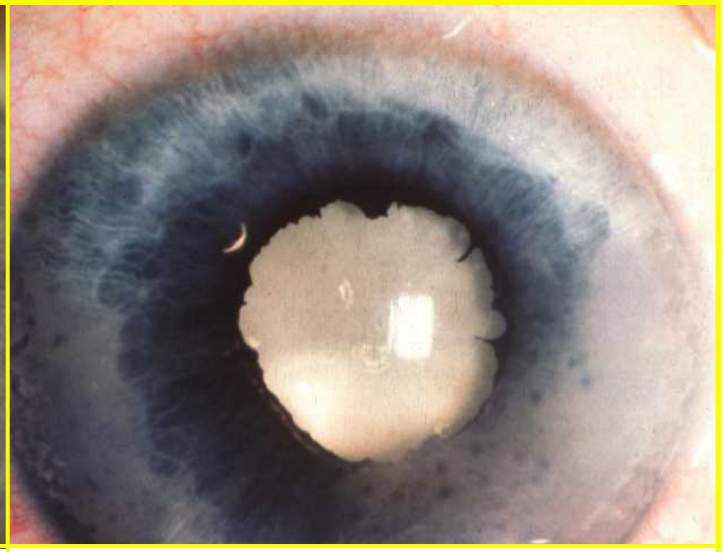

Cataract -20%

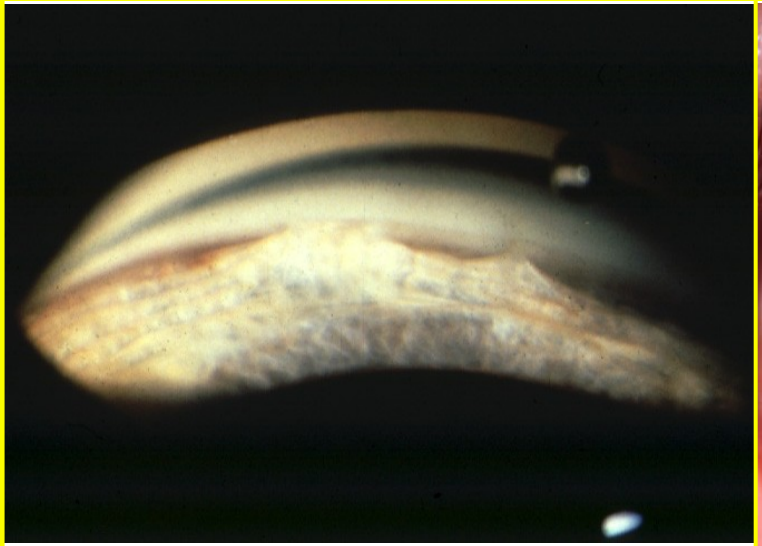

Glaucoma due to PAS - 15%

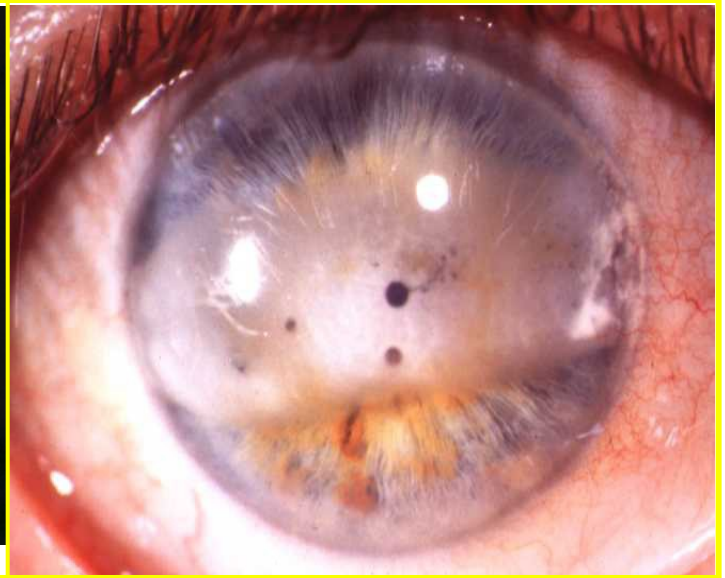

Band keratopathy - 10%

Simple episcleritis

- Common, benign, self-limiting but frequently recurrent
- Typically affects young adults
- Seldom associated with a systemic disorder

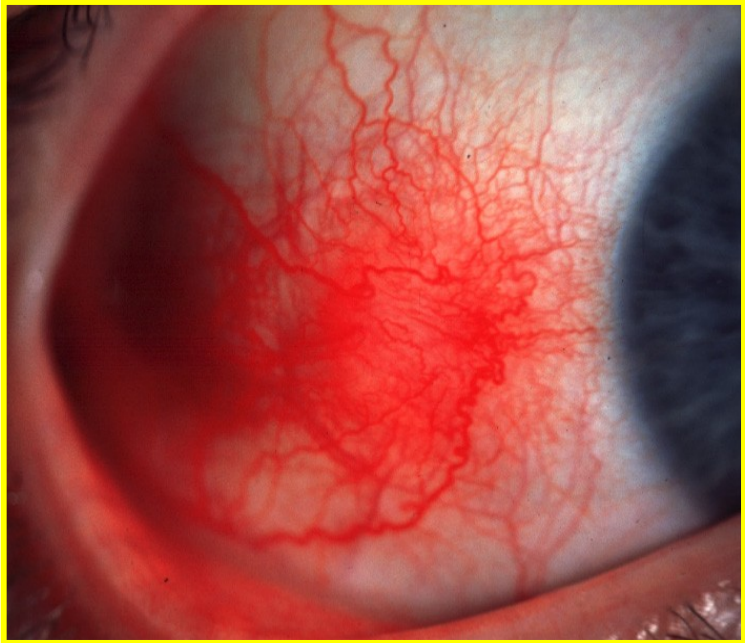

Simple sectorial episcleritis

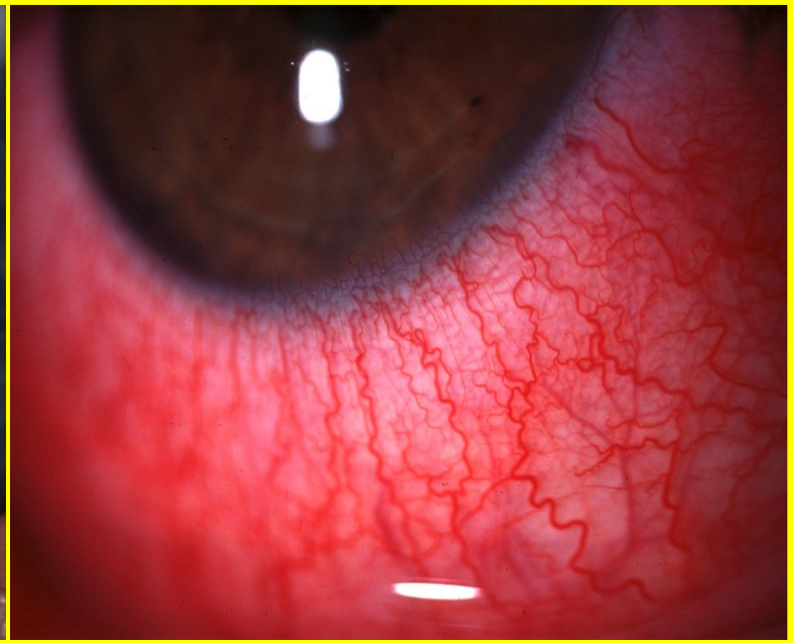

Simple diffuse episcleritis

Treatment

- Topical steroids
- Systemic ibuprofen (200 mg tid if unresponsive

Nodular episcleritis

- Less common than simple episcleritis
- May take longer to resolve
- Treatment - similar to simple episcleritis

Localized nodule which can be moved over sclera

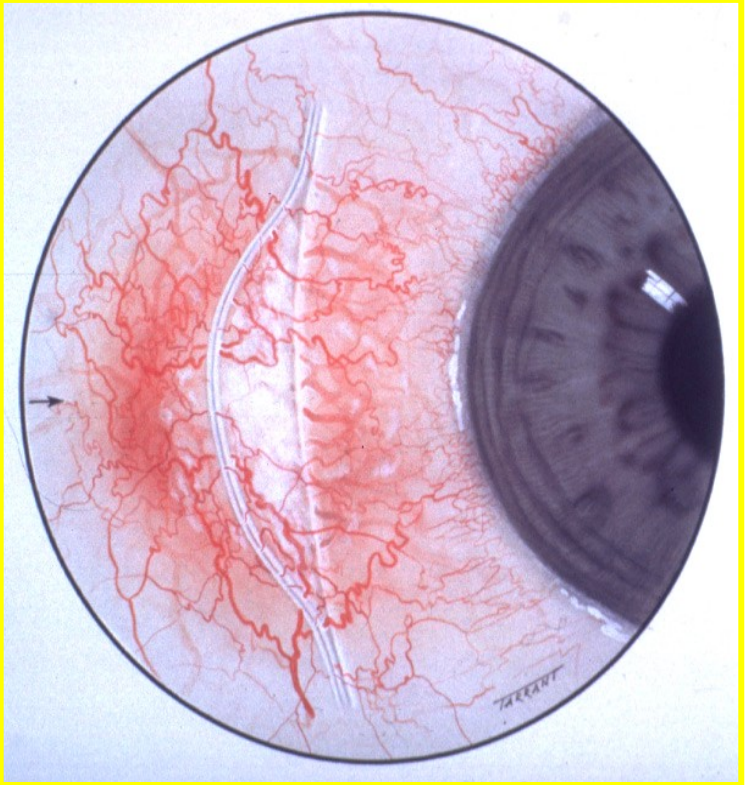

Deep scleral part of slit-beam not displaced

Causes and Systemic Associations of Scleritis

1. Rheumatoid arthritis

2. Connective tissue disorders

- Wegener granulomatosis
- Polyteritis nodosa
- Systemic lupus erythematosus

3. Miscellaneous

- Relapsing polychondritis
- Herpes zoster ophthalmicus
- Surgically induced

Diffuse anterior non-necrotizing scleritis

- Relatively benign - does not progress to necrosis
- Widespread scleral and episcleral injection

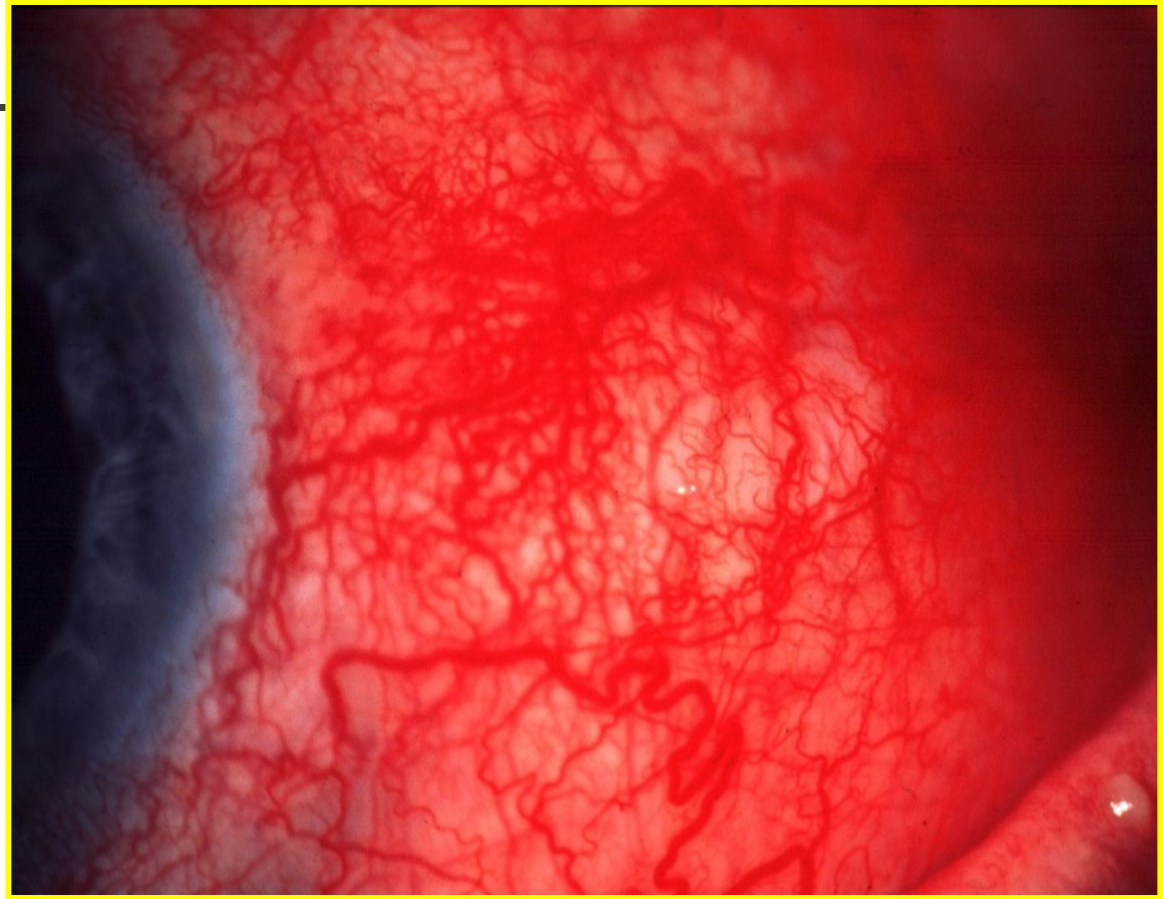

Treatment

- Oral NSAIDs
- Oral steroids if unresponsive

Nodular anterior non-necrotizing scleritis

More serious than diffuse scleritis

On cursory examination resembles nodular episcleritis

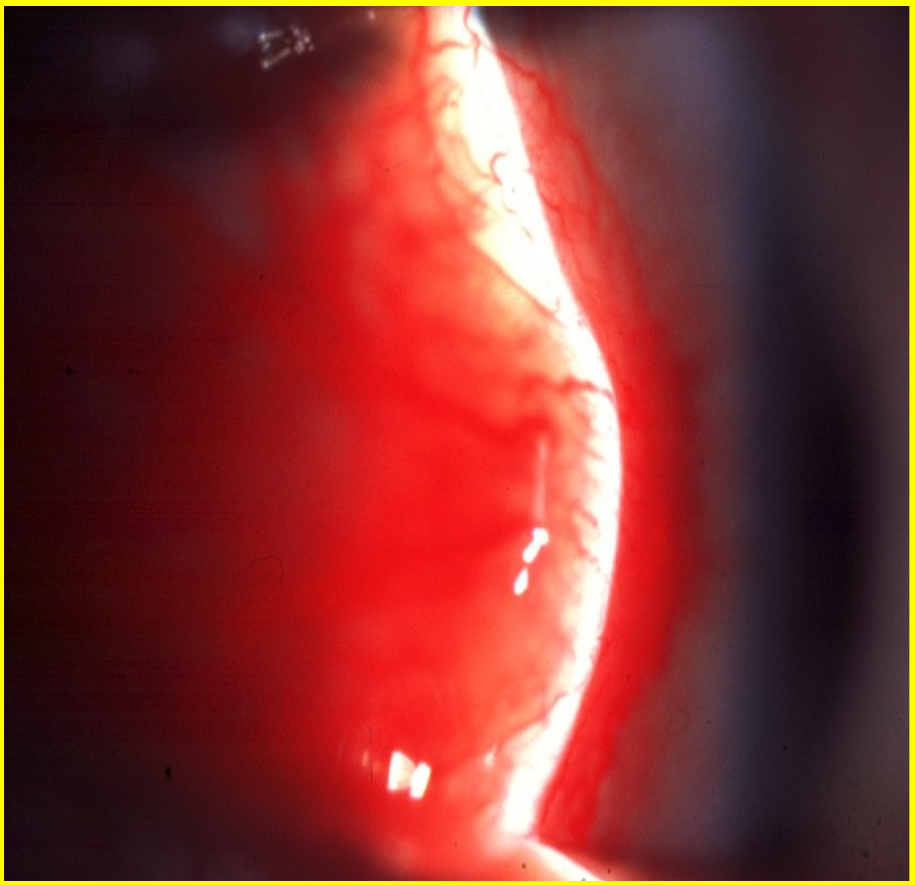

Scleral nodule cannot be moved over underlying tissue

Treatment - similar to diffuse non-necrotizing scleritis

Anterior necrotizing scleritis with inflammatio

- Painful and most severe type
- Complications - uveitis, keratitis, cataract and glaucoma

Progression

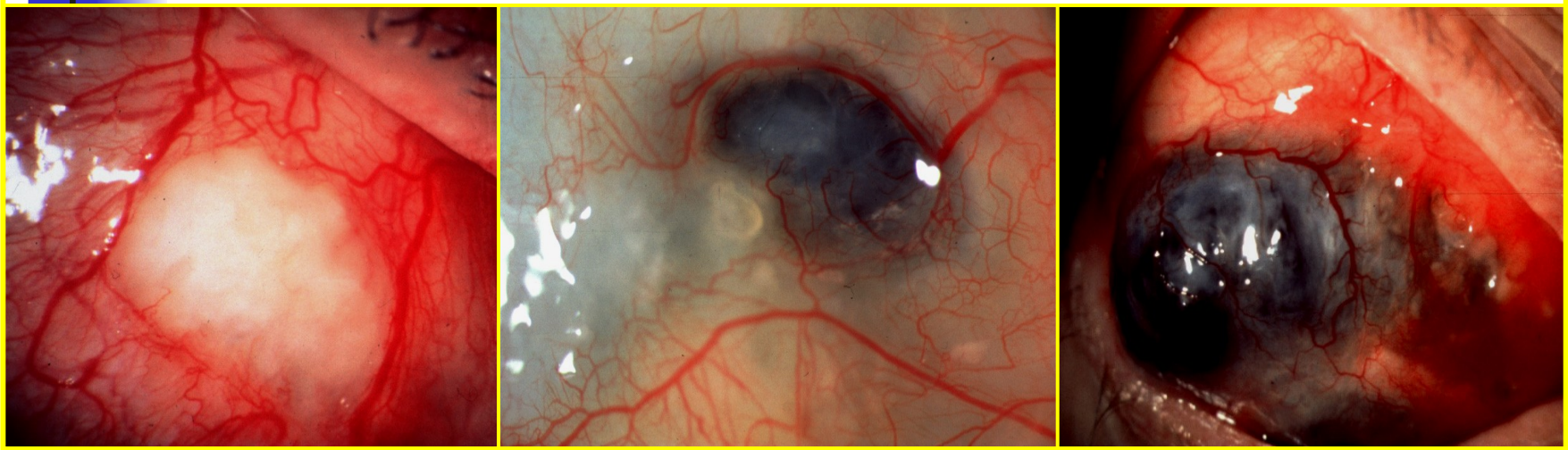

Avascular patches	Scleral necrosis and visibility of uvea	Spread and coalescence of necrosis

Treatment

- Oral steroids
- Immunosuppressive agents (cyclophosphamide, azathioprine, cyclosporin)
- Combined intravenous steroids and cyclophosphamide if unresponsive

Anterior necrotizing scleritis with inflammation (scleromalacia perforans)

- Associated with rheumatoid arthritis
- Asymptomatic and untreatable

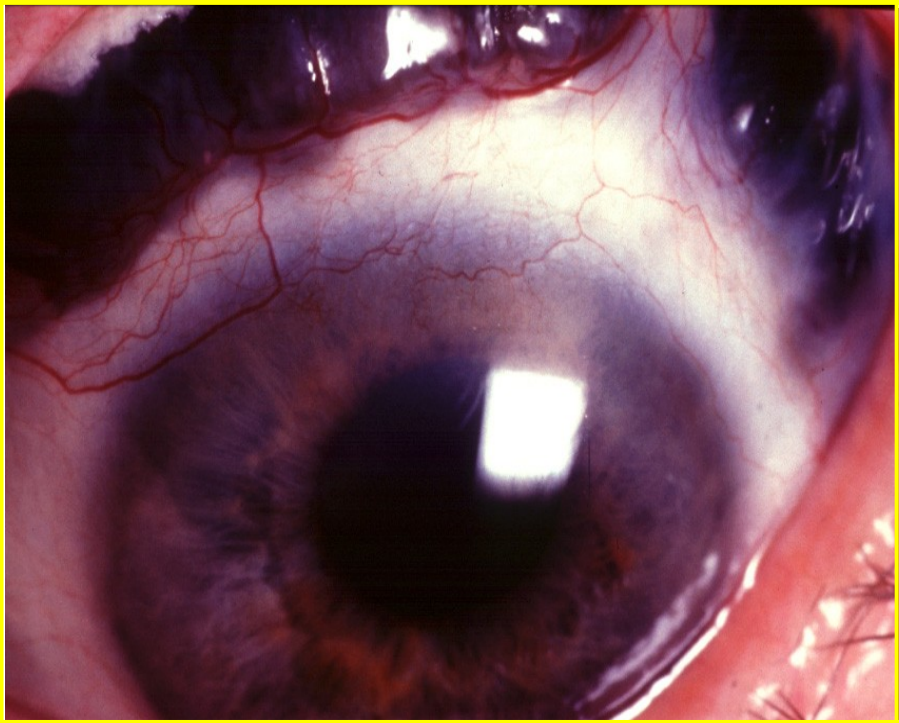

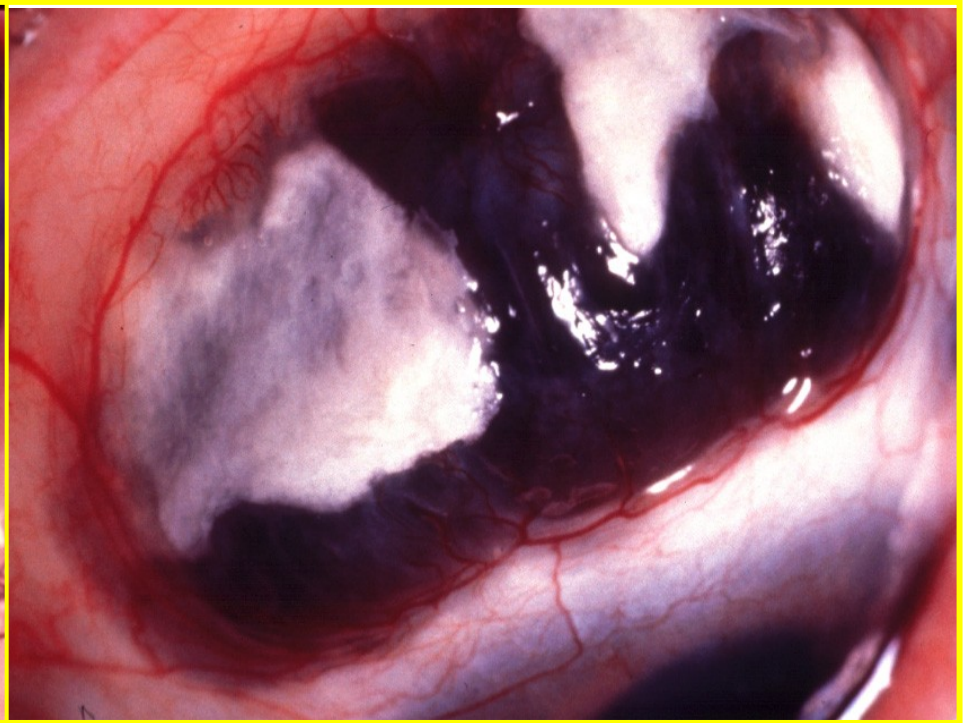

Progressive scleral thinning with exposure of underlying uvea

Posterior scleritis

- About 20% of all cases of scleritis
- About 30% of patients have systemic disease
- Treatment similar to necrotizing scleritis with inflammation

Signs

Proptosis and ophthalmoplegia

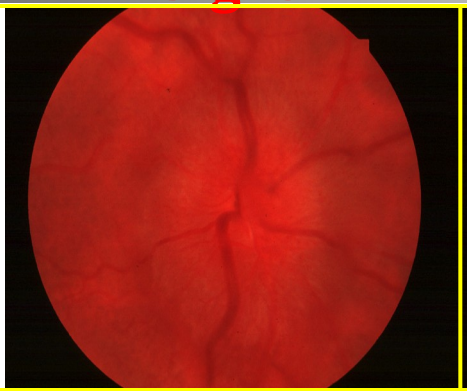

Disc swelling

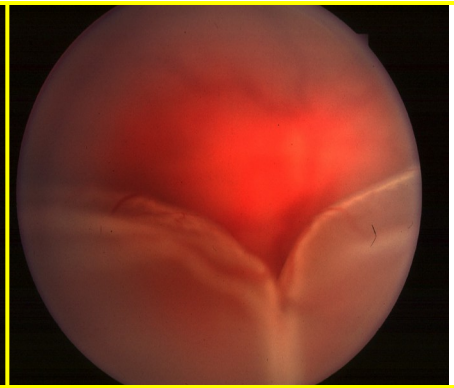

Exudative retinal detachment

Ring choroidal detachment

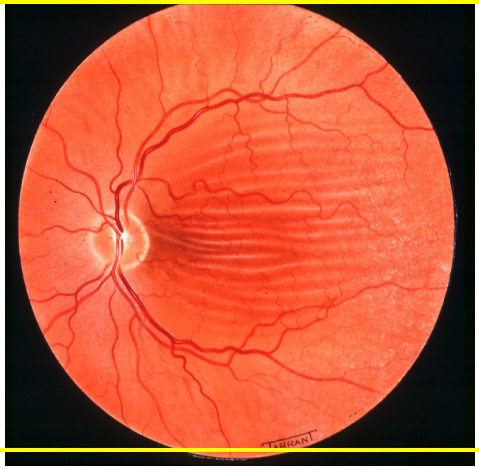

Choroidal folds

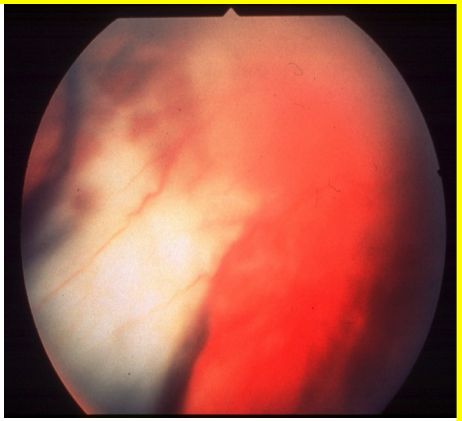

Subretinal exudation

Imaging in posterior scleritis

Ultrasound	Axial CT
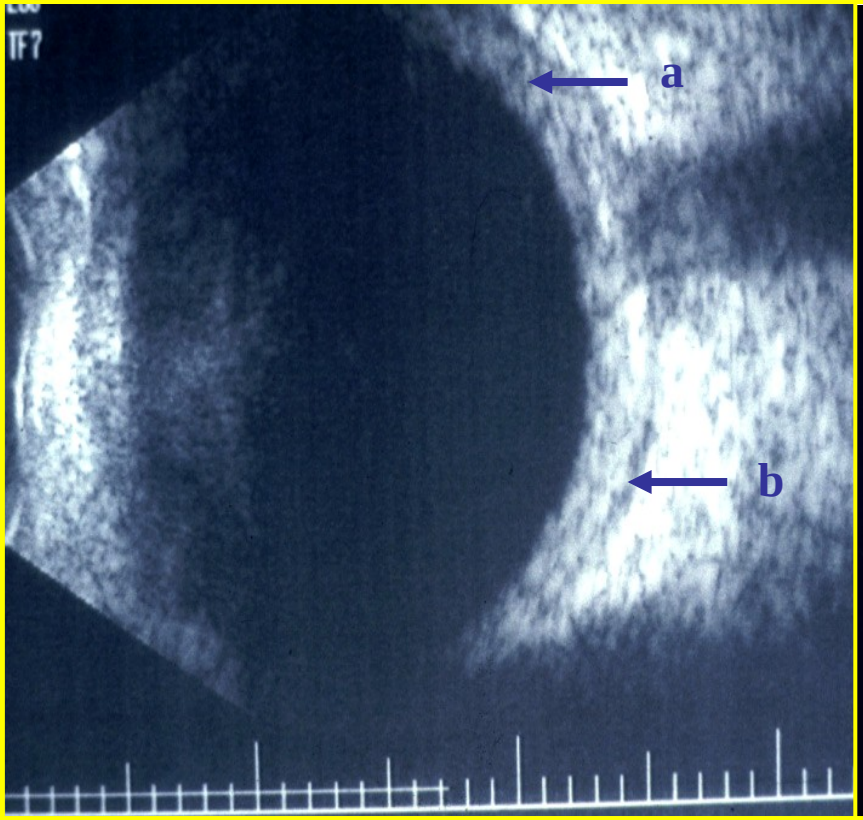	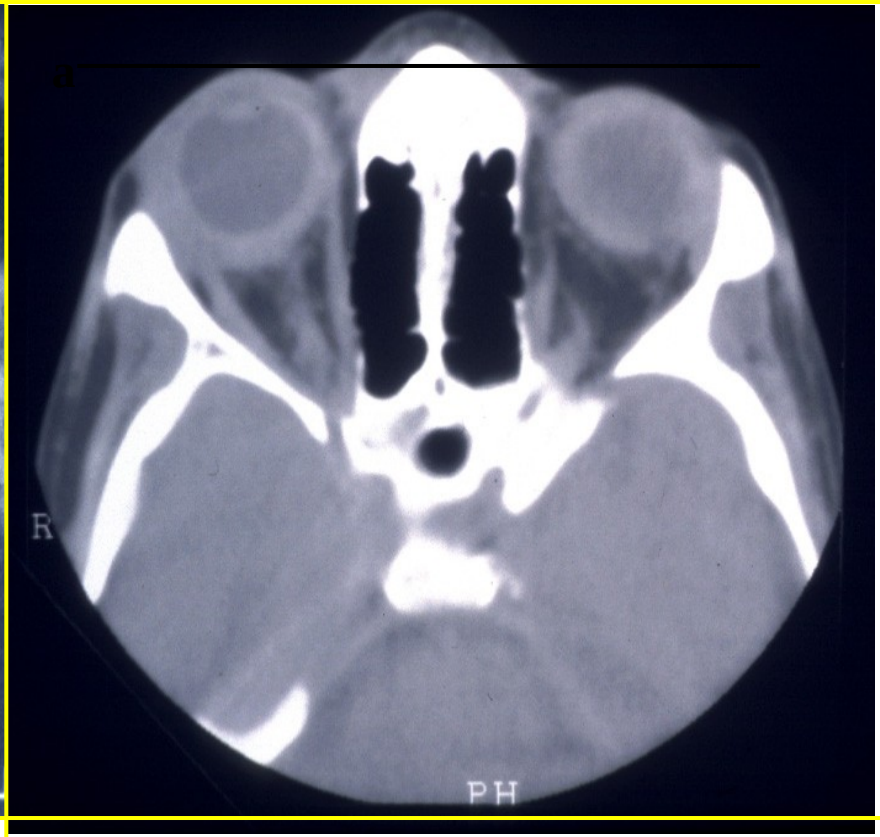
a - Thickening of posterior sclera b -Fluid in Tenon space (‘T’ sign)	Posterior scleral thickening

Acute angle closure glaucoma

- Asians, Cushites & Caucasians
- F>M
- High-strung emotional people
- Dim lighting, movies, TV soaps
- Sudden onset of pain, red eye, nausea, vomiting, headache, haloes, v.high IOPs
- Repeated episodes

Anatomical predispositions

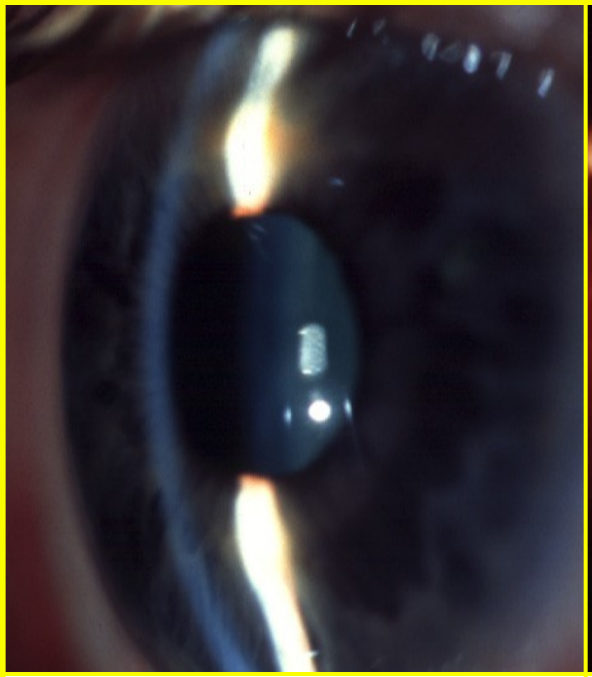

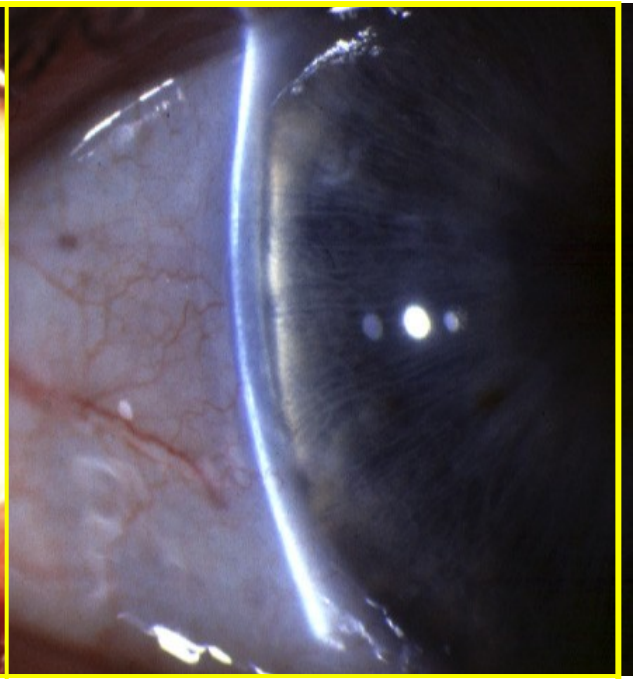

• Convex iris-lens diaphragm	• Shallow anterior chamber	• Narrow entrance to chamber angle

Pupil block

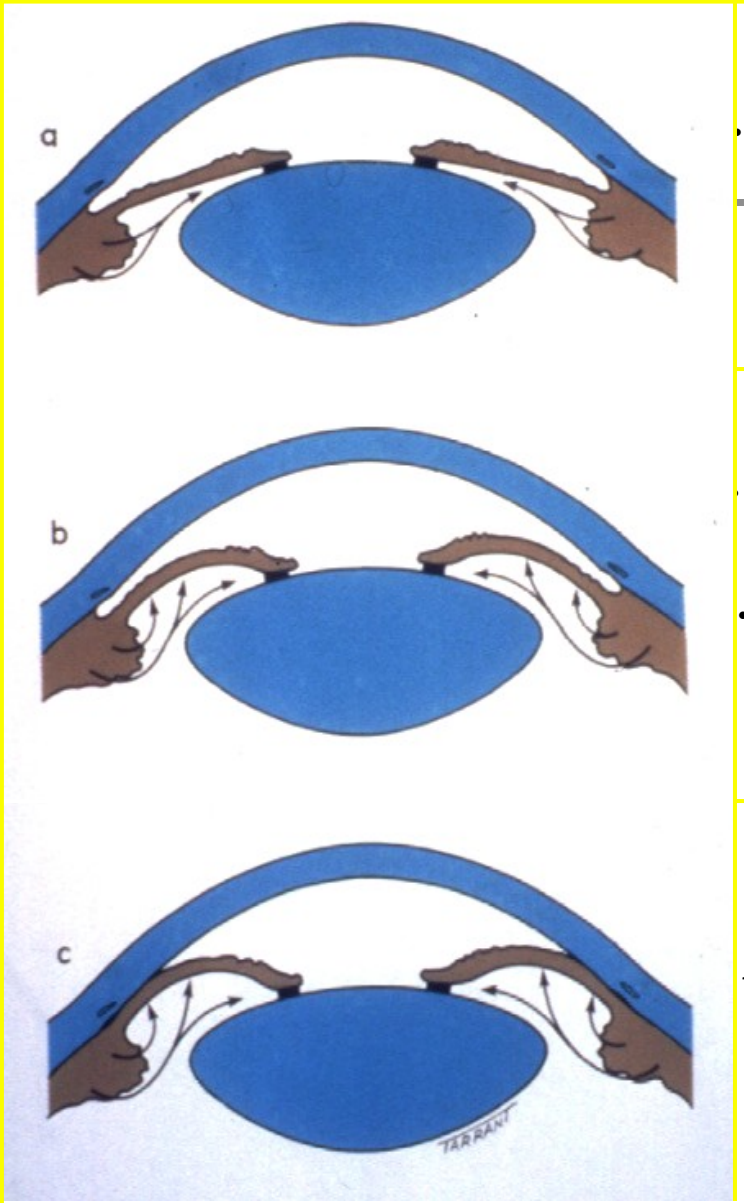

- Increase in physiological pupil block

- Dilatation of pupil renders peripheral iris more flaccid
- Increased pressure in posterior chamber causes iris bombé

Angle obstructed by peripheral iris and rise in IOP

Acute congestive angle-closure glaucoma

Signs

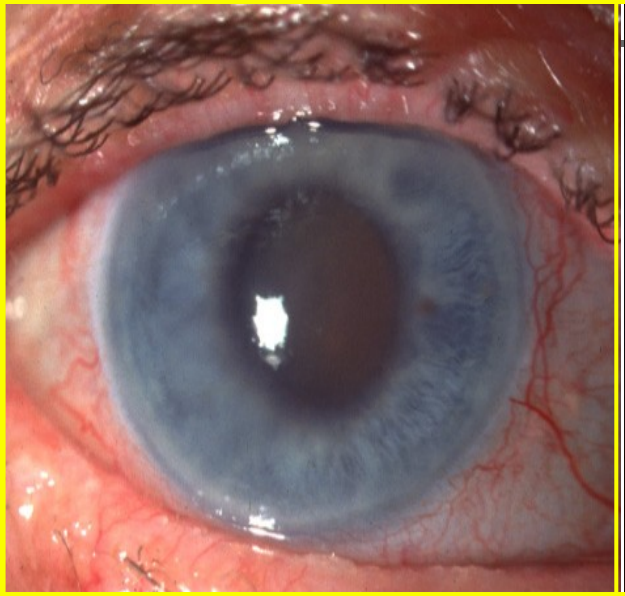

- Severe corneal oedema
- Dilated, unreactive, vertically oval pupil

- Ciliary injection
- Shallow anterior chamber

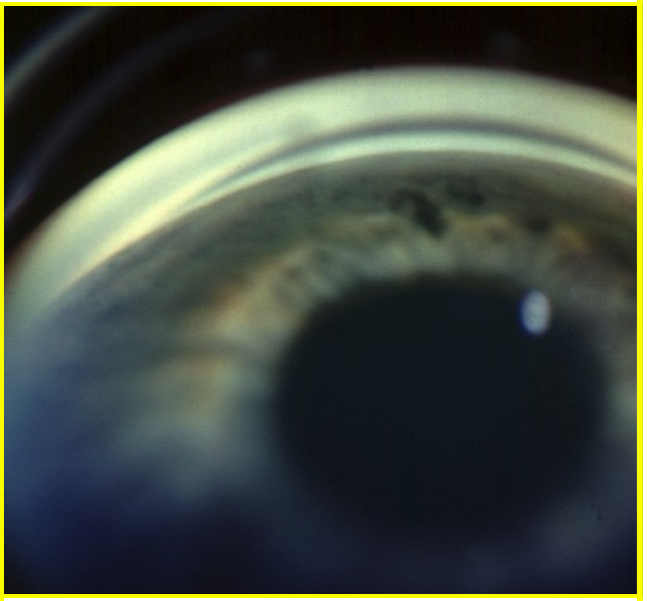

- Complete angle closure (Shaffer grade 0)

Treatment of Acute Congestive Angle-Closure Glaucoma

1. **Acetazolamide 500 mg i.v.**

2. **Hyperosmotic agents** - if appropriate
   - Oral glycerol 1-1.5 g/kg of 50% solution in lemon juice
   - Intravenous mannitol 2g/kg of 20% solution

3. **Topical therapy**
   - Pilocarpine 2% to both eyes
   - Beta-blockers
   - Steroids

4. **YAG laser iridotomy**
   - To both eyes when cornea is clear

Simple bacterial conjunctivitis

Signs

Crusted eyelids and conjunctival injection

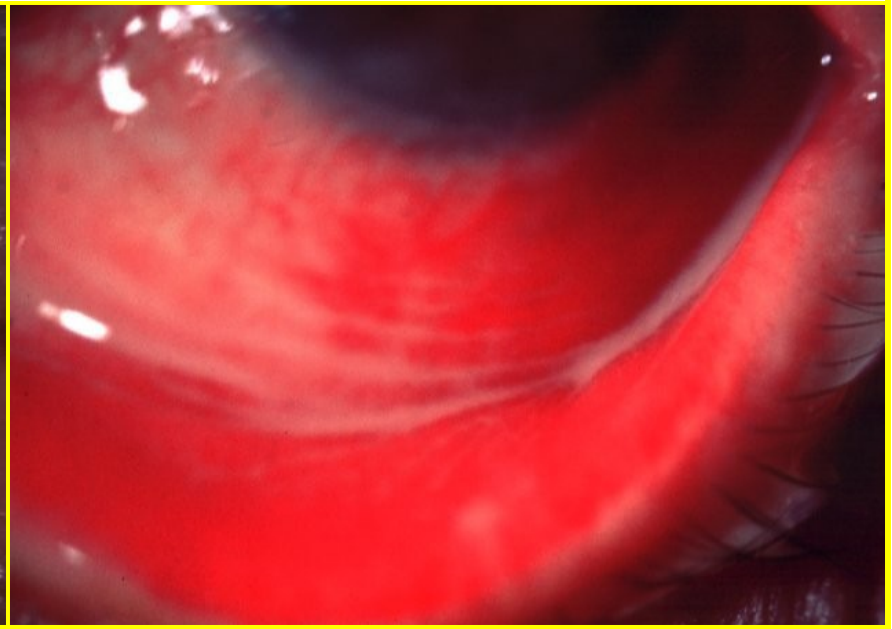

Subacute onset of mucopurulent discharge

Treatment - broad-spectrum topical antibiotics

Gonococcal keratoconjunctivitis

Signs	Complications
	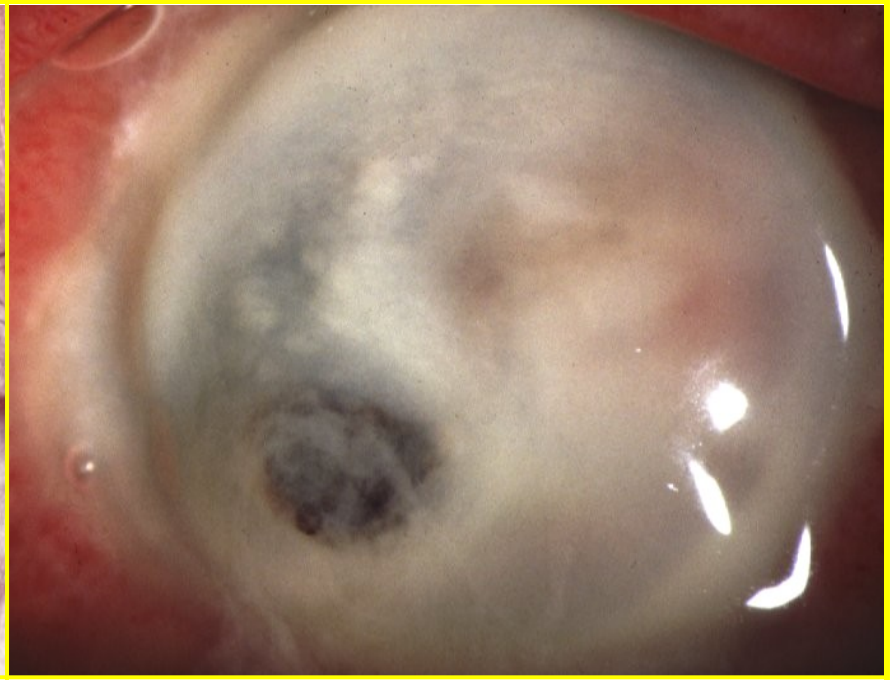
Acute, profuse, purulent discharge, hyperaemia and chemosis	Corneal ulceration, perforation and endophthalmitis if severe

Treatment

- Topical gentamicin and bacitracin
- Intravenous cefoxitin or cefotaxime

Pterygium

CHRONIC MARGINAL BLEPHARITIS

1. Anterior

- Staphylococcal
- Seborrhoeic

2. Posterior

- Meibomianitis
- Meibomian seborrhoea

3. Treatment

Staphylococcal blepharitis

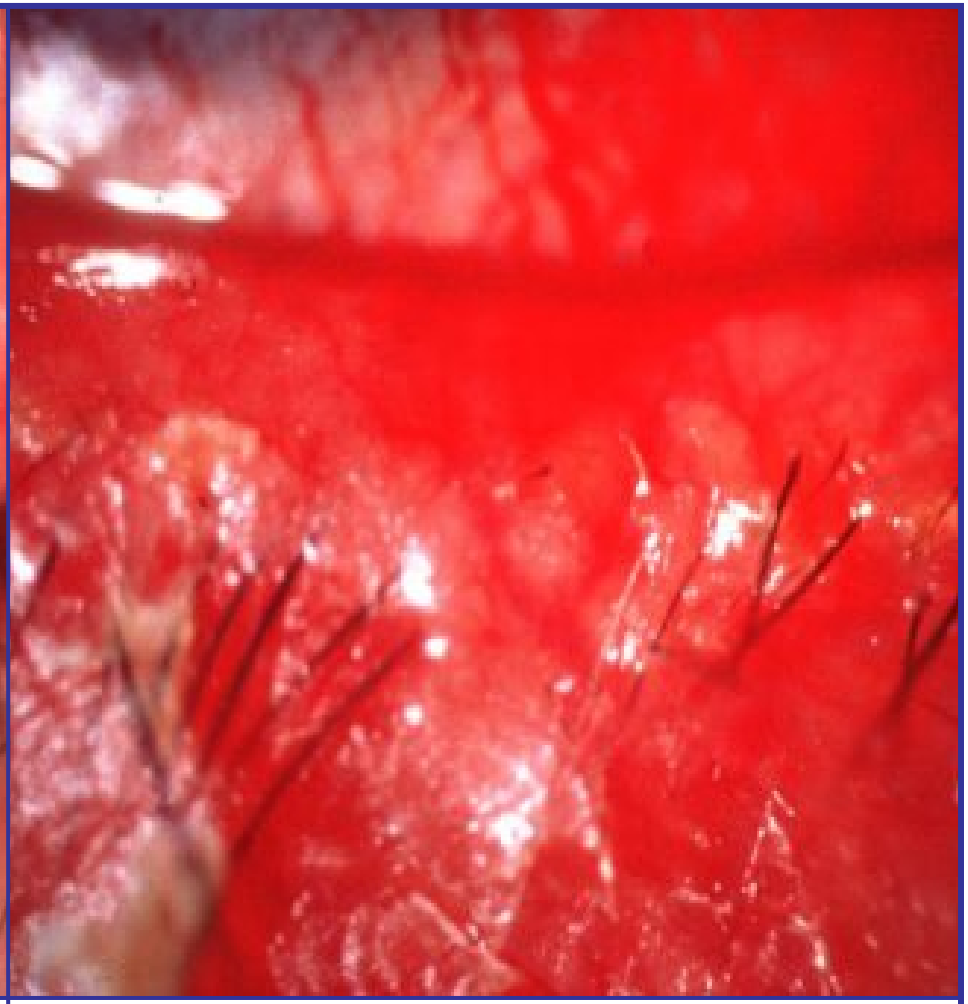

- Chronic irritation worse in mornings
- Scales around base of lashes (collarettes)

- Hyperaemia and telangiectasia of anterior lid margin
- Scarring and hypertrophy if longstanding

Treatment of Chronic Blepharitis

1. **Lid hygiene - with 25% baby shampoo**

2. **Tear substitutes - for associated tear film instability**

3. **Systemic tetracyclines - for severe posterior blepharitis**

4. **Warm compresses - to melt solidified sebum in posterior blepharitis**

Stye

- Painful nodular swelling
- Rx: warm compressions

Herpes zoster ophthalmicus

- Varicella zoster virus
- Associated with HIV/AIDS